

## THE THIRD DECADE

### THE HEAD WOUNDS OF JOHN KENNEDY: I. ONE BULLET CANNOT ACCOUNT FOR THE INJURIES by Joseph N. Riley, Ph.D.\*

The autopsy of John Kennedy remains surrounded by controversy, confusion, and conflict. There should have been a clear and unambiguous record of findings; there wasn't. The neck wound should have been dissected and the brain sectioned to better characterize the wounds; they weren't. At the very least, the brain should be available to resolve questions and controversies; it isn't. The Warren Commission accepted the conclusions of the autopsy report. Subsequent government investigations (Clark panel, Rockefeller Commission, House Select Committee on Assassinations (HSCA, cf. HSCA 7:1-6) accepted the general findings (two shots from the rear, one and only one striking John Kennedy in the head) but asserted that there was one major error (the entrance wound was relocated almost four inches above where it had been placed by the autopsy prosectors) and criticized the procedures and record of the autopsy (photographs, x-rays, notes, etc.; "x-ray" will be used throughout this paper rather than "roentgenogram"). A number of critics of the Warren Commission have argued that the autopsy findings are inconsistent with other evidence, such as the body movement shown in the Zapruder film. Some critics, e.g., Wecht (1972), largely accept the evidence but point out inconsistencies and logical problems of theories extrapolated from the findings, such as the single bullet theory. Other critics question the authenticity of the evidence. Groden and Livingstone (1988) and Livingstone (1992) question the authenticity of the photographs and x-rays and Lifton (1988) asserts that there was pre-autopsy alteration of John Kennedy's body. One need not accept the conclusions of these authors to appreciate the inconsistencies discovered and questions raised by their research. Questions of authenticity imply that the available evidence supports the conclusions---that John Kennedy was struck by two bullets, one hitting in the upper back/lower neck and one striking his head. However, if the evidence does not support these conclusions, questions of authenticity are secondary.

This paper addresses a single issue: does the available evidence support the conclusion that one bullet caused John Kennedy's head injuries? No attempt is made to resolve other issues or answer other questions related to the autopsy evidence. If John Kennedy's head wounds could not have been caused by a single bullet, the implications are obvious.

Before evaluating the evidence, crucial assumptions will be made explicit, the principal conclusions will be stated, and the rationale for the methodology will be presented. Hopefully, this will allow the reader to evaluate critically each step in the presentation and analysis of the evidence.

The working assumptions of this analysis are:

(1) All autopsy evidence (photographs, x-rays, etc.) is authentic and there has been no deliberate effort to alter the record or deceive anyone viewing the evidence.

(2) No questions of motivation will be raised. The issue is what mistakes, if any, were made, not why they were made. Major errors were made in evaluating the autopsy evidence. A scientist is responsible for accurate presentation and reasonable evaluation of evidence. Errors of fact, demonstrably in contradiction with the evidence, must be corrected without euphemism. However, such criticism is not intended to imply or suggest any ulterior motive or reason for the errors.

Methodology. In addition to considering the forensic data, this paper will emphasize neuroanatomical relationships. Specifically, it is crucial to determine if conclusions based on forensic data are anatomically consistent or even possible. If



## THE THIRD DECADE

a scientific theory cannot explain all the data, it is inadequate; if the theory leads to conclusions in contradiction with the evidence, it is invalid.

Conclusions. The fundamental conclusion of this paper is that John Kennedy's head wounds could not have been caused by a single bullet. This is not a matter of interpretation but of anatomical fact. It will be shown that crucial anatomical facts were ignored and demonstrable errors were made in interpreting the evidence.

Secondary conclusions include:

(1) The original description of a rear entrance wound by Humes et al. (1964a) ("2.5 cm lateral and slightly above the external occipital protuberance") is most likely accurate.

(2) There is little to support the assertion that the "high" entrance wound determined by the HSCA forensics panel (referred to subsequently as "Panel") and previous government panels is the entrance wound described by the original autopsy prosectors. If it is an entrance wound, it is distinct and in addition to the wound described by Humes et al. (1964a).

(3) Neither entrance wound by itself can account for all of the brain damage.

(4) There are major errors of fact and interpretation in the Panel's report.

This paper is restricted to determining if a single bullet could have caused the head wounds. No attempt is made to specify the number or origin of any additional head shots. In a subsequent paper, cortical and skull damage and associated forensic evidence will be examined in detail and possible origins of a second shot will be discussed.

### The Evidence

Several points are relevant to evaluating the evidence.

First, autopsy procedures were less than ideal. The Panel summarized a number of deficiencies in the conduct of the autopsy (HSCA 7:17):

The measures essential to a thorough medicolegal autopsy that the pathologists failed to take are:

1. Conducting the autopsy in an atmosphere free from the presence of individuals not necessary to any medical or investigative aspects of the autopsy. Aside from the Secret Service and FBI agents, it was not necessary for other military personnel to be in the autopsy room who were not performing a medical function.
  2. Consulting the Parkland Hospital doctors who administered emergency treatment to the President before initiating the autopsy. According to the medical panel of the committee, such consultation is normal procedure.
  3. Acquiring the assistance of an experienced pathologist engaged in full-time practice of forensic pathology, as opposed to the consulting capacity Dr. Finck possessed. Such experienced assistance might have prevented several errors.
  4. Recording precisely the locations of the wounds according to anatomical landmarks routinely used in forensic pathology. The medical panel of the committee stated that the reference points used to document the location of the wound in the upper back---the mastoid process and the acromion---are movable points and should not have been used.
  5. Dissecting the wound that traversed the upper back of the President. The medical panel stated that probing a wound with a finger is hardly sufficient; to ascertain the actual track, the wound must be dissected.
  6. Examining all organs and documenting the results of such examinations.
- Although the pathologists did examine most organs, they made no reference to the

## THE THIRD DECADE

adrenal glands, part of the anatomy routinely examined during the autopsy.  
7. Sectioning the brain coronally. Such documentation could have provided additional insight into the destructive impact of the missile in the brain.

Second, the quality of the preserved record (x-rays and photographs) is poor. One of the principal x-rays (frontal view of the head) is mutilated. The HSCA characterized the photographs as follows (HSCA 7:46):

1. They are generally of rather poor photographic quality.
2. Some, particularly close-ups, were taken in a such a manner that it is nearly impossible to anatomically orient the direction of view.
3. In many, scalar references are entirely lacking, or when present, were positioned in such a manner to make it difficult or impossible to obtain accurate measurements of critical features (such as the wound in the upper back) from anatomical landmarks.
4. None of the photographs contain information identifying the victim; such as his name, the autopsy case number, the date and place of the examination.

In the main, these shortcomings bespeak of haste, inexperience and unfamiliarity with the understandably rigorous standards generally expected in photographs to be used as scientific evidence. In fact, under ordinary circumstances, the defense could raise some reasonable and, perhaps, sustainable objections to an attempt to introduce such poorly made and documented photographs as evidence in a murder trial. Furthermore, even the prosecution might have second thoughts about using certain of these photographs since they are more confusing than informative. Unfortunately, however, they are the only photographic record of the autopsy.

Third, the brain, which was never examined fully, remains missing. There are additional unresolved questions about other evidence that may be missing. For example, both Humes and Stringer, one of the photographers, assert that photographs of the interior chest were taken (HSCA 7:12; HSCA 7: 253); such photographs are not a part of the record.

Finally, it should be understood that exit wounds (both neck and head) were determined by deduction rather than by direct observation. This does not mean the conclusions are wrong necessarily, but a deduction has a different standing scientifically than a direct observation.

### Description of Wounds

The Entrance Wound. A reasoned and valid interpretation of the evidence requires knowing where the bullet entered the head. Ideally, if the bullet exits, there will be unambiguous evidence of where it exited. This first consideration, the location of the entrance wound, however, is the issue most disputed between Humes et al. and the Panel. An evaluation of the evidence, presented later, strongly supports the description of Humes et al. The fundamental conclusion---that John Kennedy's head wounds could not have been caused by one bullet---does not depend on which description is more accurate.

To understand the difference between Humes et al. and the Panel, it is necessary to describe the two locations, compare them, and evaluate the evidence.

Humes et al. (1964a) described the location and characteristics of the entrance wound as follows:



THE THIRD DECADE

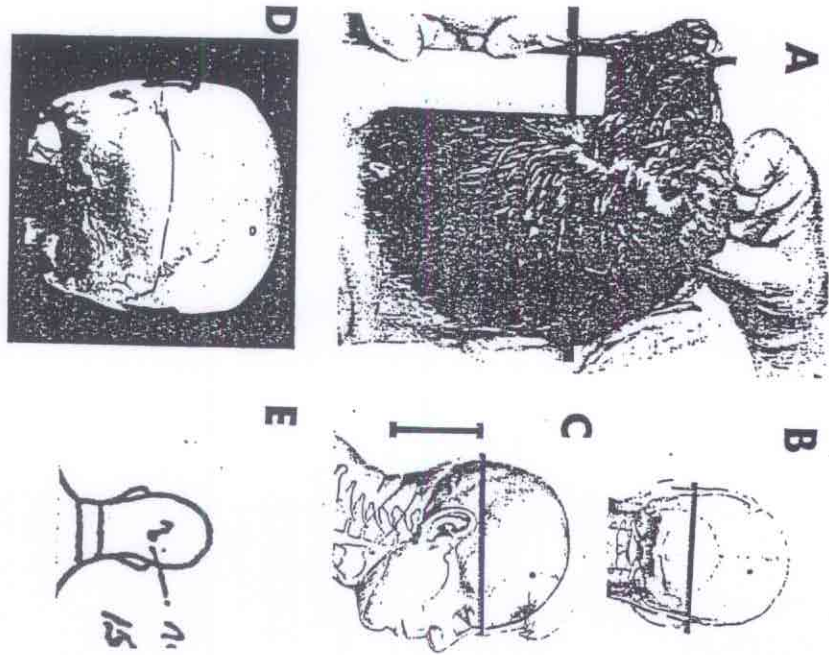


Figure 1. The Entrance Wound

A. Drawing from autopsy photograph showing the posterior scalp wound. Horizontal bar drawn from top of ear perpendicular to ruler.  
 B. Scale drawing of the back of John Kennedy's head and skull (from HSCA). Horizontal bar at top of ears approximates the level of the bar in Fig. 1A.  
 C. Scale drawing of side profile. Horizontal bar at top of ear approximates same level as Fig. 1A and 1B. Vertical bar estimates 13 cm from neck fold on X-ray shown in Fig. 1A (see text; scale values estimated from values in Figs. 2A, 2B).  
 D. Human skull marked by autopsy prosectors (lower dots) and HSCA forensics Panel E. (upper dots) to show location of entrance wound.  
 E. Portion of autopsy record showing location of entrance wound and recorded by Dr. Boswell during autopsy.

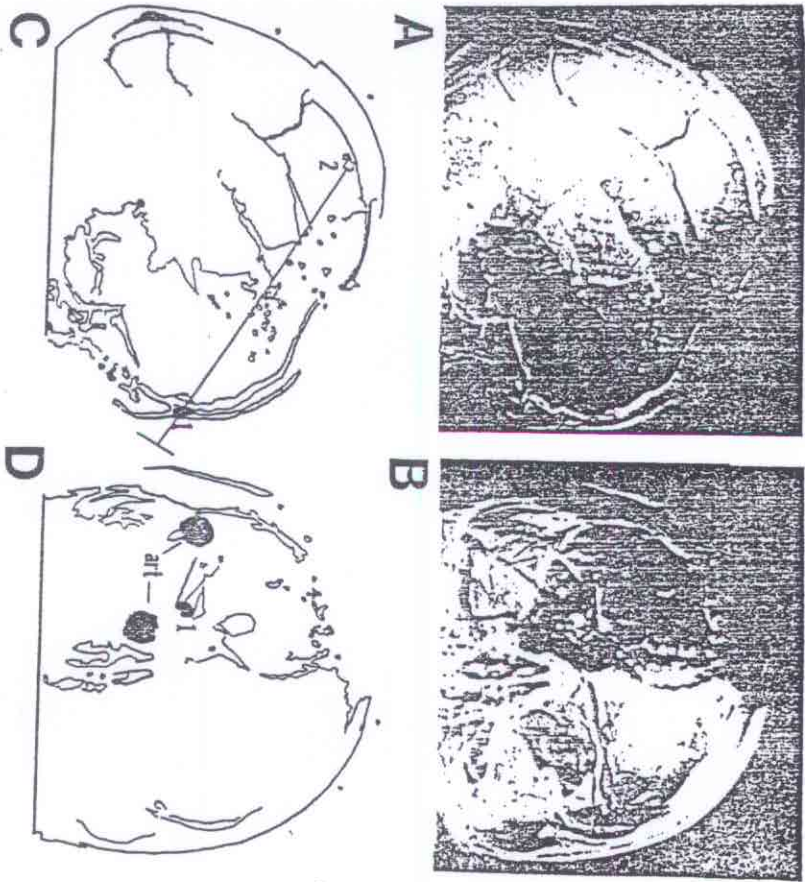


Figure 2. The X-rays

Figs. A and B. Computer-enhanced X-rays taken at start of autopsy. A - lateral view. B - frontal view. Note: Lateral X-ray has been rotated clockwise 5 degrees to compensate for external facial axis and verticles aligned. In this configuration, X-rays are isomorphic in the dorsoventral (up-down) axis.  
 C. Partial tracing of Fig. 2A used for reference. Legend: 1 - metallic fragment embedded between tables of skull at the frontal pole; note that the cross-sectional diameter and dorsoventral location are equivalent to fragment labelled '1' in Fig. 2D. 2 - large metallic fragment exterior to skull; HSCA Panel asserts that this fragment corresponds to image labelled '1' in Fig. 2B. Line drawn perpendicular to line connecting points 1 and 2 illustrates the plane of focus that would be necessary for 2 to be at location 1 in Fig. 2D; this plane is incompatible with the image in Fig. 2B.  
 D. Partial tracing of Fig. 2B used for reference. Legend: 1 - large circular metallic fragment. ar1 - artifacts (holes) created by placing a light source too close to the X-ray.

THE THIRD DECADE

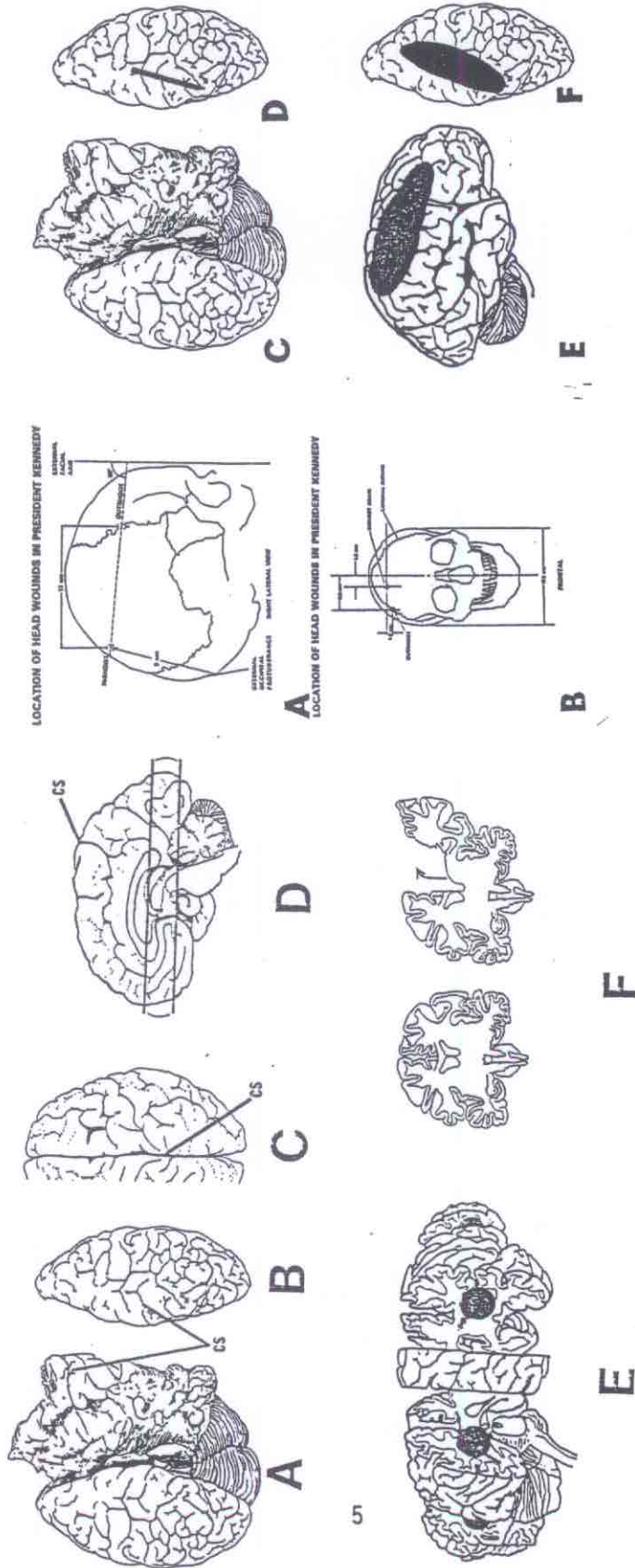


Figure 3. Subcortical Damage

A and B. Scale drawings of John Kennedy's skull showing inshoot and outshoot locations as determined by IISCA Forensics Panel (IISCA Figs. 11-6 and 11-7, IISCA 6:36).  
 C. IISCA exhibit F-302. Drawing made from photograph of brain showing subcortical damage.  
 D. "Mirror image" drawing of left hemisphere in Fig. 3A. Black line illustrates schematically the direct cortical damage predicted in Figs. 3A and 3B. Note that the direct damage predicted in 3A and 3B is limited to the cortical surface. Compare cortical damage to subcortical damage in Figs. 4A, 4D, and 4E.  
 E. Schematic illustration of distribution of metallic fragments on lateral cortical surface (drawing adapted from DeArmond et al., 1989).  
 F. Schematic illustration of distribution of metallic fragments on cortical surface, dorsal view of brain.

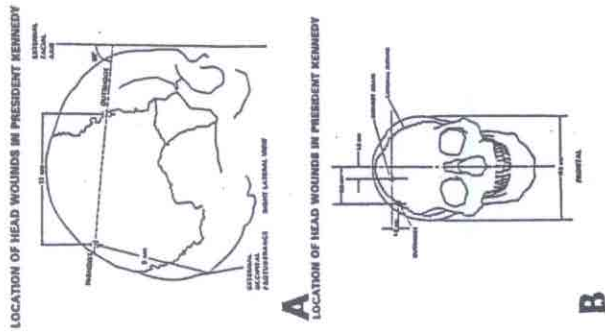


Figure 4. Subcortical Damage

Abbreviation: cs - cingulate sulcus  
 A. IISCA exhibit F-302. Drawing made from photograph of brain illustrating subcortical damage.  
 B. "Mirror image" drawing of left hemisphere in Fig. 2A. Distortion due to damage and/or post-fixation artifact is minimal.  
 C. Drawing adapted from brain atlas illustrating normal view of right hemisphere from above. Note: Identification of cingulate sulcus in Figs. 4A and 4B is unequivocal (see text).  
 D. Midline sagittal (side) view of brain. Region between horizontal lines illustrates schematically a zone of disruption that accounts for subcortical damage reported in autopsy and supplemental autopsy reports.  
 E. Schematic illustration of subcortical damage reported in autopsy and supplemental autopsy reports.  
 F. Schematic representation of post-fixation effects that accounts for the view of subcortical brain damage in Fig. 4A. Detachment of medial cortex results in "outfolding." Note that in Fig. 4A the surface area of right hemisphere is much greater than left hemisphere.  
 Figures 4C, 4D, and 4F adapted from DeArmond et al. (1989).



## THE THIRD DECADE

Situated in the posterior scalp approximately 2.5 centimeters laterally to the right and slightly above the external occipital protuberance is a lacerated wound measuring 15 x 6 millimeters. In the underlying bone is a corresponding wound through the skull which exhibits beveling of the margins of the bone when viewed from the inner aspect of the skull.

In contrast to this description, the Panel asserted that the entrance wound was located 9 cm above the external occipital protuberance and 1.8 cm lateral to the midline (HSCA 6:35; see Fig. 3A and 3B). Under normal circumstances, the observations of the autopsy prosecutors would take precedence to any subsequent examination of the autopsy record unless there is a compelling reason to reach a different conclusion. The Panel noted (HSCA 7:114,115):

The panel was concerned about the apparent disparity between the localization of the wound in the photographs and X-rays and in the autopsy report, and sought to clarify this discrepancy by interviewing the three pathologists...and the radiologist...Each was asked individually to localize the wound of entrance within any one of the above-referenced photographs after reviewing the photographs, X-rays and autopsy report. In each instance, they identified the approximate location of the entrance wound on a human skull and within the photographs as being in a position perceived by the panel to be below that described in the autopsy report [see Fig. 1D]...Each physician persisted in this localization, notwithstanding the apparent discrepancy between that localization and the wound characterized by the panel members as a typical entrance wound in the more superior "cowlick" area...

The panel continued to be concerned about the persistent disparity between its findings and those of the autopsy pathologists and the rigid tenacity with which the prosecutors maintained that the entrance wound was at or near the external occipital protuberance.

Despite the tenacity, the Panel determined that the entrance was almost four inches higher than where Humes et al. placed it. If the Panel is correct, this is a major error. An established error of this magnitude would be sufficient to raise serious questions about the validity of subsequent observations.

The Panel asserts that the entrance wound is located in the posteromedial parietal ("cowlick") area based on photographs of the scalp and x-rays. The scalp wound is illustrated in Fig. 1A. Humes' initial responses to questions about the photograph of the scalp wound resulted in some confusion and misunderstanding about the location of the wound depicted in Fig. 1A. Humes denied that the photographs demonstrated the wound and mistakenly identified an artifact near the hair line as the entrance wound. However, the Panel's evidence that the photograph illustrates an entrance wound is clear and convincing (HSCA 7:104-107). In subsequent testimony, Humes agreed that the photograph showed an entrance wound. (As an aside, Humes' so-called "retraction" in testimony to the HSCA refers to his agreement that the photographs are of the wound, and that the area he indicated previously is not an entrance site; however, Humes and Boswell continue to maintain that the entrance wound was "2.5 cm lateral and slightly above the external occipital protuberance", Breo, 1992). The Panel devoted much of its discussion of the scalp wound to refuting Humes' placement of the wound near the hairline. Unfortunately, other than asserting that the photographs show the wound in the "cowlick" area and relying on visual impressions from the photographs, the Panel fails to present any objective evidence that the scalp wound corresponds to where the Panel locates the wound on the x-rays. The question remains: based on the location of the scalp wound, where is the entrance wound on the skull? Two lines of evidence indicate that the entrance wound is not where the panel places it.

First, the Panel asserts that the scalp wound is located in the "cowlick" area. Apparently the Panel believes that the visual impression of the combed hair



## THE THIRD DECADE

establishes the location of the wound. However, it is standard forensic procedure to comb the hair around a scalp wound in order to better display it. Obviously that is the reason that the hair is parted since John Kennedy parted his hair on the opposite side of his head. In addition, even a cursory look at a picture of John Kennedy shows that his cowlick is inches above the top of the ear. The scalp wound cannot be in the cowlick area.

Rather than relying upon visual impressions, the Panel should have used objective reference points to establish the location of the scalp wound. For example, the top of the ear may be used as a reference point. In Fig. 1A, a line is drawn from the top of the ear perpendicular to the ruler. This line passes through the wound. Fig. 1B, from the HSCA report, is a representation of the back of John Kennedy's head. A line drawn from the top of one ear to the other approximates the level of the wound in Fig. 1A. This line falls inches below the point determined by the Panel and places the wound in the occipital bone and near the point of entry described by Humes et al. and illustrated by Boswell on the autopsy sheet (Fig. 1E). In the sole objective measurement the Panel makes, it notes that the scalp wound is 13 cm above the neck crease in the photograph. As shown in Fig. 1C, 13 cm above the neck crease is consistent with the description of Humes et al. but incompatible with the Panel's location of the entrance wound.

One factor that conceivably could affect the apparent location of the wound is head tilt. Head rotation (turning the head left and right) would not affect the appearance, but backward tilt (bending the neck backwards) and side tilt (bending the neck toward the shoulder) could affect the apparent location. Little side tilt is apparent. Analysis of tilt requirements required to make the Panel's location appear to be at the level at the top of the ear, assuming side tilt of no more than 10 degrees, would require a backward tilt of approximately 35 degrees; in addition, analysis of other anatomical reference points (such as the "flap" in the right frontal region) demonstrates no evidence of significant tilt.

The second line of evidence presented by the Panel to support a "high" entrance wound is visual analysis of photographs and x-rays. Since the high quality photographs and x-rays are not available to the author, the Panel's assertion that an entrance wound is present at the "high" location cannot be evaluated. However, Baden stated in his testimony (HSCA 1:301):

We, as the panel members, do feel after close examination of the negatives and photographs under magnification of that higher perforation, that it is unquestionably a perforation of entrance; and we feel very strongly, and this is unanimous, all nine members, that X-rays clearly show the entrance perforation in the skull to be immediately beneath this perforation in the upper scalp skin.

There is little doubt that the scalp wound is an entrance wound; the evidence is clear and convincing. However, the assertion that the scalp wound corresponds in location to the "high" skull entrance wound is not established. The Panel presents no objective evidence that the scalp wound is located near the "high" skull wound. The evidence, in fact, indicates that the scalp wound cannot correspond to the area determined by the Panel to be an entrance wound. Since the scalp wound cannot correspond to the "high" skull wound, the most probable alternatives are: (1) the photographs and x-rays were misinterpreted or (2) there was a second entrance wound.

One final observation about the entrance wound must be made. On the lateral x-ray (Fig. 2A), at the level of the scalp wound as determined in Fig. 1B, there is a major defect in the skull. The gross features of the defect are not inconsistent with an entrance wound; however, examination of the original x-ray and the enhanced x-ray is needed before any conclusion is made. (Unfortunately, the most caudal portion of the skull is not visible in the enhanced x-ray published by the HSCA although it is clearly evident in the original x-ray, cf. HSCA 7:110, Fig. 18). The corresponding location on the frontal x-ray is obscured by holes burned into the



## THE THIRD DECADE

x-ray by holding a light source too close to the x-ray and surrounding regions are obscured by markings that were made for anthropomorphic measurements. However, in clear copies of the frontal x-ray, there are two wedge shaped defects visible; it is possible that these defects correspond to the wedge shaped defects illustrated by Dr. Boswell on the autopsy sheet. However, this speculation cannot be considered an hypothesis without examination of the original materials.

Brain Damage and Bullet Pathways. It is not difficult to understand the brain wounds and to make reasonable deductions about the bullet pathways. Anatomically, the brain is complex and highly organized. Understanding this organization is difficult. However, once the anatomical organization is understood, it is relatively easy to determine bullet pathways. If a single bullet caused the injuries, there must be anatomical continuity between the wounds. (There are, of course, many important additional neuropathological considerations, such as contre-coup damage; however, this paper is restricted to direct mechanical disruption.) The brain is organized in one way only; in this sense, understanding the wounds is not difficult.

The description of the wounds will be divided into descriptions of the cortical and subcortical damage. The technical knowledge and vocabulary may be intimidating. However, it is not necessary to understand all of the neuroanatomical names and relationships in order to understand the pattern of the injuries.

Cortical damage. The location of the cortical damage is best appreciated in the x-rays. Using computer-enhanced x-rays, the panel described the location and distribution of fragments as follows (HSCA 7:131):

Within the right side of the head are randomly distributed, irregularly shaped, radiopaque shadows which are missile fragments. These shadows, measuring from 0.2 to 0.6 centimeters in diameter, extend from the back to the front; the largest one is present beneath the skin in front. Another group of smaller, more uniform shadows, 0.1 centimeter or less in diameter, so-called "missile dust,"...approximately paralleling the sagittal plane, and extending toward the large bony defect in the right temporal-parietal region on the right side of the head. The long axis of this grouping, if extended backward, approaches the entrance defect and missile fragment in the right side of the back of the head.

The entrance and exit points asserted by the Panel describe a relatively superficial cortical wound (Figs. 3A, 3B, 3D). If the Panel is correct, one would not expect significant disruption of cortex beyond this area of immediate impact. The area of direct cortical damage is illustrated in Fig. 3D. As would be expected, the bullet fragments are distributed over a larger area but the orientation of the fragments is consistent with the predicted direct cortical damage (Figs. 3D and 3E). Unfortunately, this region of cerebral cortex is not described in the supplemental autopsy report. It is not possible, therefore, to establish with certainty the degree or type of disruption present in the cortex damaged directly. In autopsy photographs that have become available (see Lifton, 1988, Groden and Livingstone, 1988, Livingstone, 1992) a limited view of dorsomedial cortex suggests that gyri are present and do not show massive disruption. Furthermore, the x-rays demonstrate the presence of cortical tissue due to the distribution of bullet fragments. The distribution of bullet fragments as seen in the x-rays is consistent with the entrance and exit points determined by the Panel and is perhaps the strongest evidence to support its view. Findings consistent with the Panel's view include: (1) the fragments are located in superficial cortical regions or even outside the skull; (2) the fragments are aligned roughly in a linear array in an anterior-posterior direction on the dorsolateral surface; and (3) there is no descriptive, photographic, or radiographic evidence that this region of cortex was penetrated from below as would be expected if the bullet entered near the external occipital protuberance.



## THE THIRD DECADE

Although this type of fragmentation is unusual for a copper jacketed bullet (see Appendix X, HSCA 7), it is not impossible.

In general, the Panel's description of the fragments conforms to the evidence. However, the Panel goes to great length to characterize one specific fragment and makes a major error that dramatically alters the characterization of the wounds. The fragment in question is located slightly posterior to the entrance wound asserted by the Panel and is on the surface of the skull (an unusual position in itself). The fragment is clearly visible on the lateral x-ray (Figs. 2A and 2C). According to the Panel, the large circular object in the frontal x-ray represents this fragment (Figs. 2B and 2D). The Panel's contention that this circular object represents a fragment located between the "high" entrance and exit wounds lodged between the skull and scalp is without foundation and demonstrably false. The evidence for this is unequivocal. The error will not affect the major conclusions, but correcting the error will provide a clearer understanding of the wounds. The Panel asserts that the "high" fragment corresponds to the large circular fragment located above the right orbit. The Panel writes (HSCA 7:107-109):

Skull X-ray No. 2 [Fig. 2A in present text], a lateral view of the head, reveals rather marked disruption of the smooth contour of the skull on the right side in the temporal-parietal region, with multiple fractures through other portions of the skull. There is sharp disruption of the normal smooth contour of the skull 10 centimeters (as measured on the X-ray) above the external occipital protuberance, with suggested beveling of the inner table and with fracture lines radiating superiorly and inferiorly...At this point there is an irregular, radiopaque, sharply outlined bullet fragment. [see present text Fig. 2A-2]...

The location of the missile fragment and transverse fractures of the occipital region of the skull is also apparent in the anterior-posterior X-ray view of the skull (No. 1) [present text Fig. 2B]. It shows the missile fragment to be slightly to the right of the midline and in approximately the same vertical plane as in the above-described lateral view.

It is inexplicable that the Panel would assert that the large round fragment seen on the frontal x-ray corresponds to the fragment near the asserted entrance wound on the lateral x-ray. Comparing the frontal and lateral x-rays demonstrates that it is impossible that the images correspond to the same fragment. If the x-rays are aligned so that the vertices (the vertex is the top of the skull when the body is in the standard anatomical position, i.e., standing upright) and the lateral x-ray is rotated clockwise 5 degrees to compensate for the external facial axis (see Fig. 3A), the x-rays are essentially isomorphic with respect to height, i.e., an image on one x-ray will be at the same "height" (measured from the vertex) as it is on the other x-ray. Examination of the x-rays demonstrates that it is impossible that the "high" fragment in the lateral x-ray corresponds to the round fragment in the frontal x-ray (Figs. 2A and 2B). Figure 2C demonstrates that it is impossible that the "high" fragment in the lateral x-ray could correspond to the circular fragment in the frontal x-ray. For the "high" fragment to appear to be the round fragment, the frontal x-ray would have had to have been taken in a plane of focus perpendicular to the line connecting the two fragments (Fig. 2C). The plane of focus that would be required for the "high" fragment (Fig. 2C-2) to appear at the level of the circular fragment (Fig. 2D-1) is inconsistent with the evidence. However, the location in terms of distance from vertex of the round fragment corresponds exactly with a bullet fragment located at the front of the skull at the "height" of the upper part of the frontal sinus. This corresponds, in the frontal x-ray, to the circular fragment located at the level of the right supraorbital ridge. Using an optical micrometer, the cross-sectional diameter of these two fragments is identical. (In the author's measurements, both fragments were measured to be 7mm in diameter; the Panel, using



## THE THIRD DECADE

better quality material, measured the circular fragment as 6.5mm in diameter and is almost certainly more accurate.) There can be no doubt that the large circular fragment represents a bullet fragment embedded in the right supraorbital ridge. In non-technical language, this corresponds to the bone behind the right eyebrow.

The sole rationale for this contention by the Panel is that a sharp radiopaque image usually represents an object close to the x-ray film. For example, when Humes met with the Panel, the following exchange occurred (HSCA 7:251):

DR. PETTY. Now, may I ask you one other question on this X-ray, Dr. Humes. Here is a view taken, I assume, with the radiation point above the face and the film behind the back of the head.

DR. HUMES. Not being a radiologist, I presume that.

DR. PETTY. If that's true, then the least distorted and least fuzzy portion of the radiopaque materials would be closest to the film, and we would assume then that this peculiar semilunar object with the sharp edges would be close to the film and therefore represent the piece that was seen in the lateral view---

DR. HUMES. Up by the eyebrow.

DR. PETTY. No. Up by the---in the back of the skull.

The anatomical evidence is unequivocal; however, for the sake of completeness, it may be pointed out that the clarity of a radiographic image, assuming sufficient beam intensity, depends upon the coherence ("sharpness") of the radiopaque image on the photographic emulsion. Physical factors that determine coherence include radiopaqueness (100% for a metal fragment), sharpness of the edge (minimizing beam scatter), and location relative to the radiation beam (minimizing defraction). In general, distance will correlate with clarity (the greater the distance to the emulsion, the greater the displacement due to scatter) but it is not causal. A bullet fragment in cross-section and located near the center of the radiation beam would be expected to produce an image such as that observed in the frontal x-ray. The essential points, however, are: (1) It is anatomically impossible that the "high" fragment is the circular fragment in the frontal x-ray and (2) The round fragment correlates exactly in size and location to the fragment in the lateral x-ray immediately superior to the frontal sinus.

There is a major bullet fragment embedded in the right supraorbital ridge. The evidence is unequivocal and, without qualification, the Panel is in error in equating the round fragment in the frontal x-ray with the "high" fragment in the lateral x-ray.

### Subcortical Damage

In addition to the cortical damage just described, there was massive subcortical damage. This subcortical damage was far more extensive in terms of volume of tissue damaged than the damage to the superficial cerebral cortex. In non-technical language, in addition to damage to the outside layer of the brain, there was massive damage deep inside as well extending the entire anterior-posterior length of the brain. It will be difficult, without a background in neuroanatomy, to understand the extent of this damage based solely on the written descriptions; however, it is not difficult to understand the wounds when they are placed in their anatomical relationships.

The subcortical damage is described in the Supplemental Autopsy Report (Humes et al., 1964b):

Following formalin fixation the brain weighs 1500 grams. The right cerebral hemisphere is found to be markedly disrupted. There is longitudinal laceration of the right hemisphere which is parasagittal in position approximately 2.5 centimeters to the right of the midline which extends from the



## THE THIRD DECADE

tip of the occipital lobe anteriorly. The base of the laceration is situated approximately 4.5 centimeters below the vertex in the white matter. There is considerable loss of cortical substance above the base of the laceration, particularly in the parietal lobe. The margins of this laceration are at all points jagged and irregular, with additional lacerations extending in varying directions and for varying distances from the main laceration. In addition, there is a laceration of the corpus callosum extending from the genu to the tail. Exposed in this latter laceration are the interiors of the right lateral and third ventricles.

When viewed from the vertex the left cerebral hemisphere is intact. There is marked engorgement of meningeal blood vessels of the left temporal and frontal regions with considerable associated subarachnoid hemorrhage. The gyri and sulci over the left hemisphere are of essentially normal size and distribution. Those on the right are too fragmented and distorted for satisfactory description.

When viewed from the basilar aspect the disruption of the right cortex is again obvious. There is a longitudinal laceration of the midbrain through the floor of the third ventricle just behind the optic chiasm and mammillary bodies. This laceration partially communicates with an oblique 1.5 centimeter tear through the left cerebral peduncle. There are irregular superficial lacerations over the basilar aspects of the left temporal and frontal lobes.

The Panel provides a less technical description (HSCA 7: 129):

On the right cerebral hemisphere is an anterior-posterior cylindrical groove in which the brain substance is fragmented or absent. This groove extends from the back of the brain to the right frontal area of the brain...

A description of all of the neuroanatomical structures involved is beyond the scope of this paper; however, by referring to Fig. 4D, the brain structures mentioned fall within or near the "groove" as described by the Panel. To understand this damage, it is important to keep several points in mind. First, when a bullet passes through the brain, it causes many types of damage in addition to direct mechanical damage from the missile. The multiple factors that can cause this additional damage need not be described here. The point, however, is that this wound may be viewed as a "cylinder of disruption" with a radius of approximately one inch that extends from back to front and passes through the center of the brain. Second, the wound passes near the midline. The brain is a bilateral structure but, for present purposes, it may be viewed as "joined together" except for the cerebral cortex. At the midline, the cortex "dips down" and two corresponding cortical regions (cingulate cortex) are located opposite of each other. A sheet of dura mater, termed the Falx, is located between the cingulate cortex on each hemisphere.

The subcortical damage is illustrated in Fig. 4A (HSCA exhibit F-302). (To the author's knowledge, there are no published photographs of the brain; however, the illustration is sufficient). To understand the relationship between the cortical and subcortical damage, it is crucial to understand what is shown and what is not. F-302 is NOT a view of the cortical damage ("cortical damage", as used here, refers to the dosomedial cortex described previously upon which bullet fragments were distributed). What is illustrated is partially disrupted cingulate cortex that has shifted apparent location due to the disruption of brain tissue ventral (below) to it. In non-technical language, there is an outfolding of cortex due to its detachment from the brain tissue below it (in this case, largely the corpus callosum). Schematically, this is illustrated in Fig. 4F.

This interpretation is supported by the following evidence. First, the cingulate sulcus and parietooccipital sulcus are clearly evident (Figs. 4A-4D). The "grooves" on the cortical surface (sulci, singular is sulcus) and corresponding



## THE THIRD DECADE

"ridges" (gyri, singular is gyrus) are arranged in an ordered and established pattern. The cingulate and parietooccipital sulci are located at the appropriate position and there is no configuration of sulci on the dorsolateral surface that could account for this configuration. Since it is unlikely that many readers will be experienced neuroanatomists, it must be stressed that the identification of the cingulate sulcus is beyond reasonable doubt. The cingulate sulcus is found at the posteromedial margin of the postcentral gyrus. The precentral gyrus (primary motor cortex), postcentral gyrus (primary somatosensory cortex), and the central sulcus which separates them are well defined and unambiguous cortical landmarks. It is not a matter of differing interpretations; it is a matter of attending to the facts. There is no other valid interpretation. Anatomical landmarks can be obscured or obliterated by bullet wounds; they cannot be created. Second, as reviewed previously, the evidence accumulated by the Panel demonstrates that the cortical wound was relatively superficial; there had to be cortical tissue present for fragments to be distributed so near the surface of the brain. Finally, without discussing the effects of fixation on brain tissue in detail, the increase in surface area in the right hemisphere cannot be accounted for as "flattening" of the brain (see below).

Unfortunately, misinterpretation of the anatomy has resulted in misunderstanding of the brain damage. For example, Lattimer (1972) stated "...approximately 70% of the right cerebral hemisphere was missing with only a torn and flattened portion of the base of the right hemisphere remaining." Yet, in addition to the anatomical evidence, the known fixed weight of the brain (1500 grams) makes it extremely unlikely that 70% of the right hemisphere was not present. This persistent misunderstanding and misinterpretation of the evidence continues to obscure an accurate description and understanding of the cortical damage.

Finally, the linear nature of the wound predicts the entrance and exit wounds (direction cannot be predicted, but a back to front trajectory is assumed). The alignment of the wound predicts an entrance wound in the occipital bone, lateral and above the external occipital protuberance. The exit wound, if it exists, should be in the region of the right orbit. In fact, the predicted wounds correspond to an entrance wound in the region indicated in Figs. 1B, 1C, and 1E and the predicted exit wound corresponds to the large circular fragment embedded in the right supraorbital ridge.

### Discussion

Understanding the head wounds that killed John Kennedy is a difficult task; forensic pathology and neuroanatomy are complex subjects and each has a specialized technical vocabulary. However, the misinterpretation of the head wounds is not due solely to technical issues. Missing evidence, failure to follow standard forensic autopsy procedures, and the poor quality of the preserved evidence have made the task more difficult. Conflicting descriptions and mistaken testimony have also played a role. Humes' mistaken identification of the entrance wound obscured the important question of where the scalp entrance wound was located. The Panel expended considerable effort to prove Humes was wrong rather than establishing that they were correct. Distrust has had an impact. Without considering issues other than the autopsy evidence, distrust and doubt about the autopsy evidence grew when several government panels stated that Humes et al. had made a major error in locating the entrance wound; yet the Warren Commission had used the same "erroneous" autopsy report to support its conclusions. However, much, if not most, of the controversy and conflict over the autopsy evidence is based on the premise that the evidence supported the conclusions of the government panels. Supporters of the Warren Commission findings point to the autopsy evidence to support their views. Some critics of the Warren Commission have assumed that the evidence was interpreted correctly; therefore, the evidence must have been altered. Given the highly specialized and technical knowledge required to evaluate the evidence, it is not



## THE THIRD DECADE

surprising that the interpretation of the evidence has not been challenged. However, the evidence is clear and unequivocal: John Kennedy's head wounds could not have been caused by one bullet.

Prior to discussing the evidence in detail, two points must be emphasized. First, the assertions of error and misinterpretation presented here are based on empirical issues, i.e., the questions can be answered by examining the evidence. The challenges to previous interpretations are over fundamental issues. It is not an issue based on equal validity of alternative interpretations; the challenges are either correct or incorrect based solely on the evidence. Second, it is unfortunate that the evidence has been evaluated largely on a point-by-point basis with little appreciation of logical and necessary relationships that must exist. It is not sufficient to ask "Is this an entrance wound?" without considering "If this is an entrance wound, is it consistent with the injuries and other forensic evidence?" The essential question is: can one bullet account for the head injuries? All of the damage to the head must be accounted for and be consistent with the evidence.

Since the location of the entrance wound differs significantly in the report of the HSCA forensics panel and the original autopsy report, the two views will be discussed separately. However, ultimately it will not matter which description is more accurate; neither can account for all of the head wounds.

High head wound. The HSCA Forensics Panel asserted that the single entrance wound in the skull was approximately four inches about the external occipital protuberance, in contradiction to the findings of the autopsy prosectors. There is little evidence to support the Panel's contention that the "high" entrance wound corresponds to the entrance wound described by the autopsy prosectors. To summarize evidence discussed previously:

(1) Photographs of the scalp wound do not support an entrance wound in the posteromedial parietal area. The "cowlick" is a mistaken impression and examination of anatomical relationships and landmarks in the photographic record places the wound in the occipital bone. Either the Panel is in error or the high entrance wound is a second entrance wound.

(2) The Panel's analysis of the radiographic evidence provides some support for its conclusions. Bullet fragments are distributed superficially and there is no radiographic evidence that the cortex was penetrated from below, as would be required if a single bullet entered near the external occipital protuberance. The Panel notes that such fragmentation is unusual, but not impossible, for a jacketed bullet.

(3) Inexplicably, the Panel asserts that a large metal fragment (located on the exterior surface of the skull) observed on the lateral x-ray corresponds to a large circular fragment on the frontal x-ray. It is almost inconceivable that the Panel equated the fragments; without qualification, the Panel is mistaken. The misidentification of the circular fragment has dramatic consequences for understanding the wounds. There is clear and compelling evidence that the large circular fragment represents a fragment embedded in the right supraorbital ridge. If the fragment is embedded in the supraorbital ridge, it is difficult, if not impossible, to explain how a bullet that has a trajectory almost tangential to the skull (see Figs. 4A and 4B) could fragment extensively in the superficial brain layers, have major portions of the bullet exit (based on fragments recovered in the limousine), yet a large fragment (which retains a circular profile) deviates down to penetrate the supraorbital ridge but no fragments are distributed along the pathway.

These issues raise serious questions about the validity of the Panel's analysis. However, there is an even more compelling reason to reject the Panel's conclusions. The Panel describes the subcortical damage adequately (see previous description) but provides no analysis or explanation of how such wounds could be produced. If a bullet entered where the Panel places the entrance wound, it is anatomically impossible to produce the subcortical wounds. A description of the trajectory necessary to produce the subcortical wounds borders on parody (to those not anatomically inclined, some characteristics of the required trajectory include:



## THE THIRD DECADE

immediately upon entry, a large fragment must break off, change trajectory by at least 60-70 degrees, descend approximately 5 cm, split again, with each fragment changing trajectory by 90 degrees, the fragments must be at 180 degrees to each other, both trajectories must parallel the midline, each fragment must have sufficient energy to produce extensive tissue disruption along the trajectory, and so on). Even the most superficial examination of the evidence demonstrates that the high entrance wound cannot account for all of the posterior subcortical damage, yet the Panel provides no explanation or analysis of the subcortical wounds. It is difficult to understand how a panel of competent forensic pathologists could have ignored the subcortical damage in their report.

Clearly, the "high" entrance wound does not and cannot account for the observed subcortical damage.

Occipital Entrance Wound. The original description of an entrance wound "2.5 cm lateral and slightly above the external occipital protuberance" is consistent with the preserved record. The autopsy prosectors have consistently and "tenaciously" (in the words of the Panel) maintained this is the location of the entrance wound. To briefly summarize the evidence from the preserved record:

(1) The photographic evidence of the scalp wound is consistent with this location.

(2) The radiographic evidence is inconclusive. On the lateral x-ray, there is an area of damaged skull that corresponds to the location predicted by the analysis of the photographs of the scalp wound. The corresponding area on the frontal x-ray is mutilated. Therefore, the radiographic evidence is inadequate to make any definitive statement in support of the original location of the entrance wound by the autopsy prosectors.

(3) The occipital entrance wound is consistent with the subcortical wounds. As described previously, the subcortical damage requires an entrance and exit wound in the occipital bone and the right supraorbital ridge due to the linear nature of the damage. A large circular bullet fragment is embedded in the right supraorbital ridge. In addition, the two bullet fragments that were recovered during the autopsy were removed from the region of the right frontal pole.

The conclusion that follows from these data is that John Kennedy was struck in the back of the head at or near the point described by Humes et al. (1964a), the bullet followed a straight trajectory, and embedded in the right supraorbital ridge. However, this entrance site and trajectory cannot account for the cortical damage and cannot be the wound inflicted at frames 312/313 of the Zapruder film.

First, there is no evidence of continuity between the cortical and subcortical wounds. There is no evidence of significant fragmentation along the subcortical trajectory and no anatomical or radiographic evidence of a path from the subcortical trajectory and the damaged cortex. In addition, as described previously, the distribution of fragments in the cortex is superficial, without evidence of subcortical penetration, and the pattern of distribution is inconsistent with a subcortical penetration.

Second, the trajectory cannot be reconciled with the head shot shown in the Zapruder film. The HSCA conducted an extensive trajectory analysis based on the position of the head as seen in frame 312. Using the "high" entrance wound, the HSCA demonstrated that the trajectory could be aligned with "the southeast sixth story window of the Texas School Book Depository" (HSCA 6:62). However, the trajectory of the occipital entrance wound differs significantly from the trajectory of the "high" entrance wound. The trajectories differ a minimum of 18 degrees in the horizontal plane and 5 degrees in the vertical plane. Even a cursory plotting of these differences in HSCA figures II-11 and II-12 (HSCA 6:41-42) demonstrates that the occipital entrance wound and associated subcortical wounds could not have been caused by a shot from the Texas School Book Depository corresponding to Zapruder frame 312/313.



## THE THIRD DECADE

An entrance wound located in the posteromedial parietal area, as determined by the HSCA Forensics Panel, may account for the cortical damage but cannot account for the subcortical damage. An entrance wound in the occipital region, as determined by the autopsy prosectors, may account for the subcortical damage but cannot account for the dorsolateral cortical damage. The cortical and subcortical wounds are anatomically distinct and could not have been produced by a single bullet. The fundamental conclusion is inescapable: John Kennedy's head wounds could not have been caused by one bullet.

\*4951 Francis Drive, Silverdale, WA 98383

### BIBLIOGRAPHY

- Abbreviation used: HSCA#: Refers to volume:page(s) of Report of the House Select Committee on Assassinations, L. Stokes, Chairman (1979) Washington, D.C.: U.S. Government Printing Office.
- Breo, D.L. (1992) JFK's death -- the plain truth from the MDs who did the autopsy. JAMA, 267:2794-2803.
- DeArmond, S.J., M.M. Fusco, and M.M. Dewey (1989) Structure of the Human Brain. New York: Oxford Univ. Press.
- Groden, R.J., and H.E. Livingstone (1989) High Treason. New York: Conservatory Press.
- Humes, J.J., "J" T. Boswell, and P.A. Finck (1964a) Autopsy protocol, Commission Exhibit No. 387, Report of the President's Commission on the Assassination of President John F. Kennedy. Washington, D.C.: U.S. Government Printing Office, pp. 538-543.
- Humes, J.J., "J" T. Boswell, and P.A. Finck (1964b) Supplementary report of autopsy number A63-272, Commission Exhibit No. 391, Report of the President's Commission on the Assassination of President John F. Kennedy. Washington, D.C.: U.S. Government Printing Office, pp. 538-543.
- Lattimer, J. (1972) Observations based on a review of the autopsy photographs, x-rays, and related materials of the late President John F. Kennedy. Res. Staff Phys., May, 1972, cited in Lifton (1988) 470.
- Lifton, D.S. (1988) Best Evidence. New York: Carroll & Graf.
- Livingstone, H.E. (1992) High Treason 2. New York: Carroll & Graf.
- Wecht, C.H. (1972) Pathologist's review of JFK autopsy: An unsolved case. Modern Medicine, reprinted in Scott, P.D., P. L. Hoch, and R. Stetler (1976) The Assassinations. Dallas and Beyond. New York: Vintage Books, pp. 228-236.

### MORE ABOUT THE HEAD WOUND

by  
Charles A. Putensen\*

Most people upon viewing the Zapruder film will immediately say that it is obvious that this shot came from the front since the body is thrown rearward. The logical explanation is that President Kennedy is thrown back and to the left because the bullet came from the right front.<sup>1</sup> The conclusion is that since witnesses heard shots from the grassy knoll it means this assassin fired the fatal head shot seen in frame Z-313.

Most people also know that when a bullet pierces through an object that the contents are always driven in the direction of travel with the bullet. Thus, if we study the evidence left by the distribution of the cranial tissue we should be able to deduce the trajectory of this bullet.

Mrs. Kennedy climbed onto the trunk lid of the limousine to retrieve part of her husband's skull. This is substantiated by her Secret Service Agent, Clinton Hill.<sup>2</sup>



## THE THIRD DECADE

Billy Harper found a part, identified by Dr. A.B. Cairns an occipital bone on the grass south of Elm Street.<sup>3</sup> The Harper fragment was twenty five feet from where the President was at the moment of the fatal shot.<sup>4</sup> Officer B.M. Hargis drove his motorcycle six to eight feet behind the left rear fender just a little back and left of Mrs. Kennedy. He was hit with tissue with such impact that he thought that he had been shot.<sup>5</sup> Motorcycle officer B.J. Martin to his left had bloodstains on the left side of his helmet because he was looking right after the first shot.<sup>6</sup>

Dr. McClelland of Parkland Hospital said the right rear portion of the head was blasted out.<sup>7</sup> This is supported by testimony of Drs. Perry, Carrico, Peters, Akin, Jones,---just about all the Dallas doctors.

The entrance wound appears to be tangential in front of the ear near the hairline of the right temple. This obliterated part of the temporal<sup>8</sup> and all the parietal and occipital lobes before laceration of the cerebellum. Acting on official instructions, technicians of Time-Life retouched photographs of the Zapruder film to make this appear as an exit wound.<sup>10</sup> Blood pressure caused the cloud of red blood to last nearly a second.<sup>11</sup> In the clear copy of the Zapruder film we see the brain tissue rain down on the trunk of the limousine.

To deduce the location of the assassin we need to orient the President's head and the limousine to the geometry of Dealey Plaza. Secret Service driver Greer had just driven into the left lane from the center lane of Elm Street. After the neck wound, President Kennedy was held erect by his back brace as he slumped left towards his wife. His head was tipped down and 34° left.<sup>12</sup> Elm Street declines and also angles away from Abraham Zapruder to merge with Main Street. We now see that the bullet that entered in front of his right ear and exited in the right rear portion of the head had to come from the direction of the Triple Underpass. If the physical distribution of the cranial evidence is fact, as I believe, then this is my only logical conclusion.

The view through the assassins' gunsights must have been that President Kennedy's head eclipsed the south curb of Elm Street next to Officer Hargis and between Officer Martin. By my hypothesis, the bullet this time went over the windshield because the car has traveled down the incline. The frangible bullet enters the skull in the right temple. As the bullet exits it blasts bone loose. Parietal bone is torn loose over the right rear trunk while the 5cm, X 7cm. Harper fragment is flung onto the grassy curb. The bloody brain material is splattered on the motorcycle officers, especially Billy Hargis.

Israeli Intelligence, the Mossad, believe that all professionals will do a job in the same way and there are few places they would choose.<sup>13</sup> Christian David said Lucien Sarti had considered the railroad bridge after taking photographs of Dealey Plaza.<sup>14</sup> Gordon Arnold wanted to photograph the parade from the Triple Underpass but was told to get out by someone showing CIA identification.<sup>15</sup> James Altgens, photographer for the Associated Press in Dallas tried to station himself on the Triple Underpass but was shooed away by a Dallas policeman.<sup>16</sup>

S.M. Holland, an employee of The Union Terminal Company, was asked by police officers to identify railroad employees who wanted to watch the motorcade from the bridge.<sup>17</sup> He said, "...there was quite a few that came up there right in the last moments."<sup>18</sup>

President Kennedy's assassination was the work of magicians. It was a stage trick complete with accessories and false mirrors, and when the curtain fell the actors, and even the scenery, disappeared. The magicians were not illusionists but professionals.<sup>19</sup> During the resulting confusion that is bound to occur they would have time to escape. I doubt if even they thought the evidence wouldn't be thoroughly examined and that they would have this much time.

\*RR#1--Box 245, Spencer, IA 51301



## Notes

1. JFK. Warner Bros. film. 1991.
2. Mark Lane, Rush to Judgement, (Thunders Mouth Press, 1992) p. 57.
3. David Lifton, Best Evidence, (New York: Carroll & Graf, 1988) p. 504.
4. Robert Groden and Harrison E. Livingstone, High Treason (New York: Berkley Books, 1990) p. 43.
5. Jim Marrs, Crossfire: The Plot that Killed Kennedy, (New York: Carroll & Graf, 1989) p. 73.
6. Marrs, Crossfire, p. 15.
7. Groden and Livingstone, High Treason, p. 42.
8. Lifton, Best Evidence, p. 308.
9. Charles Crenshaw, M.D., JFK Conspiracy of Silence, (Signet Books, 1992) p. 86.
10. James Hepburn, Farewell America, (Vadus[Liechenstein]: Frontier Publishing Co., 1968) p. 385.
11. Hepburn, Farewell America, p. 386.
12. Ned Scott, Jr., "The Myth of the Grassy Knoll Gunman," The Third Decade, Vol. 8#5, July 1992, p. 22.
13. Scott Van Wynesberghe, "Stray Shots VII: What the Mossad Knows," The Third Decade, Vol. 7#6, September 1991, p. 19.
14. Anthony Summers, Conspiracy (New York; Paragon House, 1989) pp. 524-525.
15. British Central Television (London) "The Men Who Killed Kennedy", October 1988.
16. Marrs, Crossfire, p. 33.
17. Lane, Rush to Judgement, p. 33.
18. Sylvan Fox, The Unanswered Questions about President Kennedy's Assassination, (New York: Award Books, 1965) p. 96.
19. Hepburn, Farewell America, p. 281.

## INSIGHTS ON THE X-RAYS

by  
Jerry Organ\*

Monte Evans' fine review of High Treason 2 (September, 1992 issue) omitted more than one "annoying error." Among them: Livingstone's charge of missing frontal bone in the X-rays, the core of his thesis.

Of course, the "missing" frontal bone is nothing more than normal luminosity best seen when the actual X-ray films are back-lit. The President's X-rays were cropped, and may have been purposely printed poorly by the HSCA out of deference to the family. Dr. McDonnel reported the frontal bone present (1 HSCA 205) and Dr. Wecht, who also examined the films, did not report anything so unusual. (Jim Moore, Conspiracy of One, p. 109).

Critics who assert the frontal bone is "missing," Lifton (p. 707) and the High Treason books, have never published the President's ante-mortem lateral X-ray (1 HSCA 241). (See Figure 1) Could the reason be that it also conveys the false impression of "missing" bone in the frontal region? Even Livingstone's normal X-rays (following p. 432) show the frontal bone white like the background and would likewise "disappear" if printed negatively (black background) like the autopsy X-rays.

An exasperated Dr. Levine repeatedly told Livingstone: "What you need to do is look at the original X-ray films." (p. 354) Until then, it's adventurous to make claims on the basis of the X-rays as printed by the HSCA, unfortunately the only source available to the public. The reports of Drs. Levine, Davis, McDonnel, Chase and Seaman (1 HSCA 153-76, 200-14), HSCA consultants who actually reviewed the original radiographs, confirm the skull wound locations as seen in the autopsy photographs and Zapruder film, and described in the autopsy report.